

# Case Report: Aviation Pulmonary Embolism in Pregnancy

K. Mardiana<sup>\*1,a</sup>, R. J. Abigail<sup>1,b</sup>, Y. K. Yee<sup>1,c</sup>, L. Soe<sup>1,d</sup> and H. N. Suharjono<sup>2,e</sup>

<sup>1</sup>Department of Obstetric and Gynaecology, Faculty of Medicines and Health Sciences, University Malaysia Sarawak, 94300 Kota Samarahan, Sarawak, Malaysia

<sup>2</sup>Department of Obstetric and Gynaecology, Sarawak General Hospital, Jalan Hospital, 93586 Kuching, Sarawak, Malaysia

<sup>\*</sup>kmardiana@unimas.my, <sup>b</sup>abigail.jerip@gmail.com, <sup>c</sup>kyee@unimas.my, <sup>d</sup>lsoe@unimas.my, <sup>e</sup>harrissuharjono@gmail.com

**Abstract** – *This case report discusses an expanding demographic: Aviation-related venothromboembolism (VTE) in pregnancy. As the number of commercial flights increase and the notion of travel gains popularity, the obstetrician is certain to meet an increasing number of at-risk mothers bound for a long haul flight. The pregnancy state itself being hypercoaguable, studies show that air-travel specific conditions namely immobility, dehydration and hypobarica which leads to thrombus formation. Despite VTE being a leading cause of maternal mortality in world wide, specific preventive protocols regarding the at-risk pregnant flier remain scarce-to-nil. Data has shown that compressive stockings alone remain insufficient. The much-debated role of injectable thromboprophylaxis pre-flight is discussed here. Data and studies regarding oral anticoagulants for prevention and treatment of VTE are fast rising and their roles in pregnancy explored. In summation, evidence irrevocably shows that the risks of VTE outweigh that of bleeding. However, the imperative for thromboprophylaxis in at risk pregnant fliers is still controversial. Copyright © 2016 Penerbit Akademia Baru - All rights reserved.*

**Keywords:** veno-thromboembolism, pulmonary embolism, air travel, thromboprophylaxis

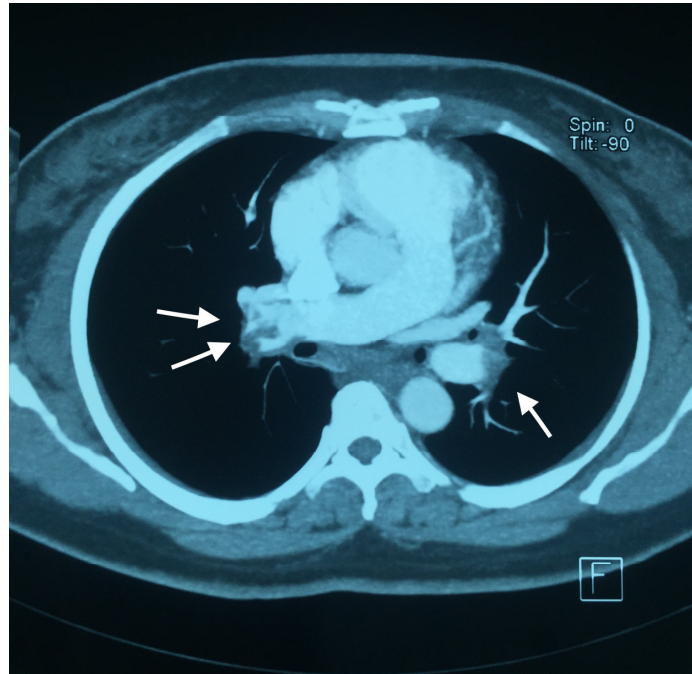
## 1.0 INTRODUCTION

Venothromboembolic diseases remain one of the leading cause for maternal mortality in Malaysia. The hypercoagulable state during pregnancy doubles the risk of thromboembolism when coupled with air travel. A long journey over four hours alongside immobilization and low cabin pressure are the main triggers for thrombus formation. Most aviation companies have yet to produce a standard preventive protocol for the at risk pregnant women taking long haul flights.

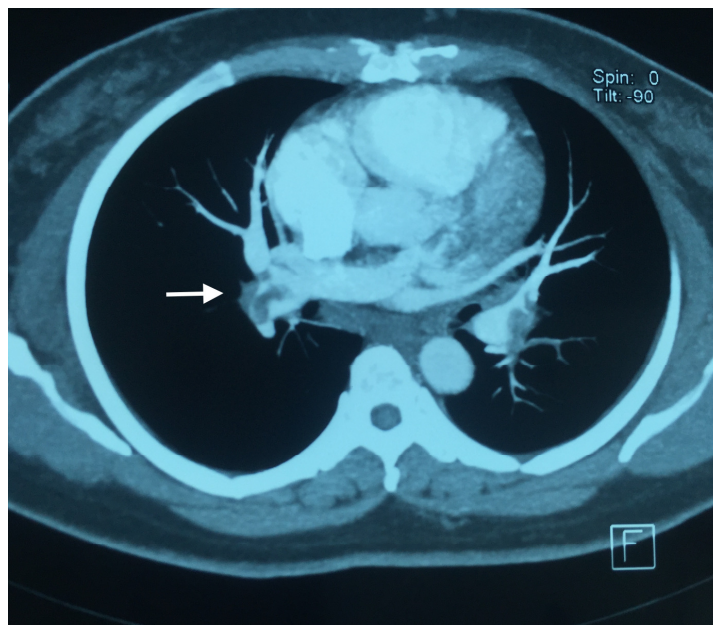
## 2.0 CASE REPORT

A 36 years old Chinese woman in her sixth pregnancy boarded a long haul flight (about 18 hours) in early pregnancy. She was about 13 weeks pregnant at the time, sans prior venothromboembolic (VTE) event. History drew nil for calf tenderness, contraceptive usage or surgery before this presentation. Five days after the flight, she presented to the emergency unit

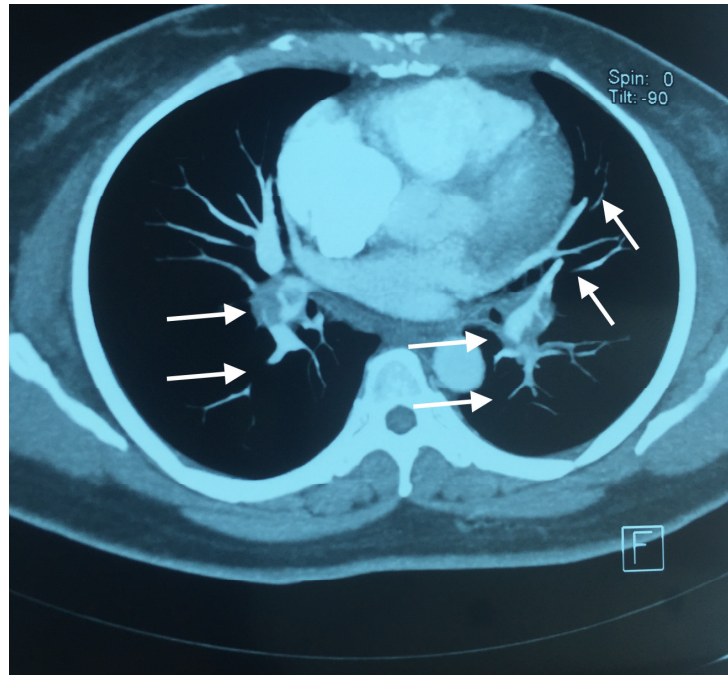
complaining of shortness of breath, which started during the flight and worsening over the past 3 days. Her risk factors then were advanced maternal age, multiparity, obesity, pregnancy and long flight.



**Figure 1:** CTPA with arrows showing filling defects bilaterally.



**Figure 2:** CTPA with arrow showing filling defects and thrombus of the left pulmonary artery.



**Figure 3:** CTPA with arrows showing filling defects bilaterally.

On admission, she was comfortable in recumbence, comprehensible and speaking with full sentences during the interview. There was no evidence of calf tenderness or positive cardiovascular findings other than tachycardia. The chest x-ray showed cardiomegaly, the lower limbs Doppler ultrasonography was negative for evidence of deep vein thrombosis; echocardiography yielded normal findings. In view of her multiple risk factors for VTE, a Computerized tomography scan of the pulmonary arteries (CTPA) was done and showed extensive bilateral pulmonary embolism involving the main pulmonary arteries extending to its branches (Figure 1, 2, 3).

The patient was started on subcutaneous tinzaparin and under close monitoring by obstetrician and physician throughout her pregnancy.

### 3.0 DISCUSSION

Pregnancy is known to increase the risk for thromboembolism by 4-10 times [1, 2, 4] compared to the non-pregnant state. This risk is present from the first trimester [3] and is at the highest in the third trimester [2]. Post partum, this risk increases 100-fold in the immediate first week post partum [1] and remains at 20- to 80-fold until 6 weeks post partum [1, 2].

Air travel is one significant factor for VTE risks. Symptomatic VTE in a healthy young individual after a 4-hour flight is 1:6000 [5] and this risk increases with flight duration: 4-folds over 8 hours, and 8-folds over 12 hours [6]. A recent meta-analysis has shown dose relation where the relative risk for thrombosis increases 26% every 2 hours of flight duration [7]. A cohort study [9] estimates that compared to not flying, the risk of thrombosis after long-haul flights remained 3.2-fold increased which normalized over an eight-week window.

Together, pregnancy-related physiological changes and air-travel beyond 4 hours heightens the thromboembolic risk exponentially. It is not solely the immobility of long haul flights that contribute, but also the hypoxic-hypobaric cabin environment [8] as reported by several studies. The risk of venous thrombosis in a pregnant woman travelling by air is calculated to be 1 per 1000 pregnant air-travellers. (The risk of venous thrombosis in non-pill using women who travel by air is 1:5000 travellers [9], while pregnancy leads to increased risk of thrombosis 5-fold [2]).

Hence, this patient was at risk of thromboembolism in view of her multiple risks factors (high BMI, age more than 35, multiparity, long distance travel and ex-smoker). According to Green top guidelines [18], she requires antenatal thromboprophylaxis throughout her pregnancy and postpartum period. However, the role of thromboprophylaxis and mechanical prophylaxis are still controversial in view of sparse data regarding the aviation thromboembolism especially during pregnancy.

Current available guidelines, as published by the British Thoracic Society [10], identify three risk-groups under which pregnancy and 0-2 weeks postpartum is stratified as middle risk; while the American College of Chest Physicians [11] distinguishes 1 increased risk group. In summary, both guidelines recognize high-risk groups and validate their need for thromboprophylaxis. While data comparing mechanical and medical prophylaxis remains scarce, it can be reasoned that Low Molecular Weight Heparins (LMWHs) is to be preferred over below knee stockings for it is a well established prophylaxis. Further more, stockings only work properly in combination with leg muscle movement.

The Green top guideline recommends that women should have their risks discussed and the reasons for individual recommendations explained, citing weight-adjusted dose of LMWHs as the agents of choice for antenatal and postnatal thromboprophylaxis [18]. Their role as the preferred prophylaxis of air-travel-related thrombosis is based on its ability to prevent coagulation activation in a hypobaric chamber [17]. While practices vary in different countries, LMWH by self-injection is the preferred anticoagulant due rapid onset and long-haul coverage (half life ranging 4-6hours post SC administration [19]). A prophylactic dose (0.5mg/kg), one hour before take off, is advisable in pregnant patients with one more risk factors for thrombosis (including height <150cm or >190cm). However, there is not much evidence that recommends the duration of the treatment, although theoretically the risk of VTE persists up to eight weeks post travel.

The risk of bleeding in LMWH usage is noteworthy, as this could be an even bigger hazard when travelling. Studies have shown the risk of major bleeding in LMWH users is 0.14% (95% CI 0.04-0.50%; 2 cases out of 1475 treated [12-15]) on treatment for several weeks. This risk must be substantially lower for a 1-2 days treatment course (estimated 10-fold), assuming the average treatment period is 10 days, while travellers will only be treated for 1 day. Data shows that the risks of VTE outweigh that of bleeding, hence the imperative for thromboprophylaxis in at risk mothers.

Novel oral anticoagulants like Rivaroxaban, Dabigatran, and Apixaban have garnered much popularity. A meta-analysis of several trials shows Dabigatran to be non-inferior to LMWH for VTE prophylaxis [20] with a reduced risk of major hemorrhage. However, in 2014 the ACOG reported a study showing direct ex vivo evidence of Dabigatran and its prodrug crossing a term human placenta [21] rendering this drug best avoided in pregnancy.



#### 4.0 CONCLUSION

Undoubtedly, air travel in at-risk pregnant women significantly increases the risk of VTE yet the proper preventive guidelines are lacking. Mechanical methods alone are insufficient. However, the role of injectable thromboprophylaxis for high-risk women is still debatable due to its method of administration, potential side effects and the efficacy to prevent the thromboembolic event. Oral anticoagulants still remain unadvisable to be used in pregnancy.

#### REFERENCES

- [1] Heit, John A., Catie E. Kobbervig, Andra H. James, Tanya M. Petterson, Kent R. Bailey, and L. Joseph Melton. "Trends in the incidence of venous thromboembolism during pregnancy or postpartum: a 30-year population-based study." *Annals of internal medicine* 143, no. 10 (2005): 697-706.
- [2] Pomp, E. R., A. M. Lenselink, F. R. Rosendaal, and C. J. M. Doggen. "Pregnancy, the postpartum period and prothrombotic defects: risk of venous thrombosis in the MEGA study." *Journal of Thrombosis and Haemostasis* 6, no. 4 (2008): 632-637.
- [3] James, Andra H., Margaret G. Jamison, Leo R. Brancazio, and Evan R. Myers. "Venous thromboembolism during pregnancy and the postpartum period: incidence, risk factors, and mortality." *American journal of obstetrics and gynecology* 194, no. 5 (2006): 1311-1315.
- [4] Martinelli, Ida, Valerio De Stefano, Emanuela Taioli, Katia Paciaroni, Elena Rossi, and Pier Mannuccio Mannucci. "Inherited thrombophilia and first venous thromboembolism during pregnancy and puerperium." *Thrombosis and haemostasis* 87, no. 5 (2002): 791-795.
- [5] Samama, Meyer-Michel. "An epidemiologic study of risk factors for deep vein thrombosis in medical outpatients: the Sirius study." *Archives of internal medicine* 160, no. 22 (2000): 3415-3420.
- [6] Cannegieter, Suzanne C., Carine JM Doggen, Hans C. van Houwelingen, and Frits R. Rosendaal. "Travel-related venous thrombosis: results from a large population-based case control study (MEGA study)." *PLoS Med* 3, no. 8 (2006): e307.
- [7] Chandra, Divay, Emilio Parisini, and Dariush Mozaffarian. "Meta-analysis: travel and risk for venous thromboembolism." *Annals of internal medicine* 151, no. 3 (2009): 180-190.
- [8] Schreijer, A. J. M., M. F. Hoylaerts, J. C. M. Meijers, H. R. Lijnen, S. Middeldorp, H. R. Büller, P. H. Reitsma, F. R. Rosendaal, and S. C. Cannegieter. "Explanations for coagulation activation after air travel." *Journal of Thrombosis and Haemostasis* 8, no. 5 (2010): 971-978.
- [9] Kuipers, Saskia, Suzanne C. Cannegieter, Saskia Middeldorp, Luc Robyn, Harry R. Büller, and Frits R. Rosendaal. "The absolute risk of venous thrombosis after air travel: a cohort study of 8,755 employees of international organisations." *PLoS Med* 4, no. 9 (2007): e290.
- [10] Ahmedzai, S., I. M. Balfour-Lynn, T. Bewick, R. Buchdahl, R. K. Coker, A. R. Cummin, D. P. Gradwell et al. "Managing passengers with stable respiratory disease

- planning air travel: British Thoracic Society recommendations." *Thorax* 66, no. Suppl 1 (2011): i1-i30.
- [11] Kahn, S. R., W. Lim, A. S. Dunn, M. Cushman, F. Dentali, E. A. Akl, D. J. Cook et al. "American college of chest physicians. Prevention of VTE in nonsurgical patients: antithrombotic therapy and prevention of thrombosis: American college of chest physicians evidence-based clinical practice guidelines." *Chest* 141, no. 2 Suppl (2012): 195S-226S.
- [12] Ramos, Jorge, Carla Perrotta, Gustavo Badariotti, and Graciela Berenstein. "Interventions for preventing venous thromboembolism in adults undergoing knee arthroscopy." *The Cochrane Library* (2008).
- [13] Testroote, Mark, Willem Stigter, Dianne C. de Visser, and Heinrich Janzing. "Low molecular weight heparin for prevention of venous thromboembolism in patients with lower-leg immobilization." *Cochrane Database Syst Rev* 4 (2008).
- [14] Marlovits, Stefan, Gabriele Striessnig, Raimund Schuster, Roland Stocker, Monika Luxl, Siegfried Trattnig, and Vilmos Vécsei. "Extended-duration thromboprophylaxis with enoxaparin after arthroscopic surgery of the anterior cruciate ligament: a prospective, randomized, placebo-controlled study." *Arthroscopy: The Journal of Arthroscopic & Related Surgery* 23, no. 7 (2007): 696-702.
- [15] Goel, D. P., R. Buckley, G. Abelseh, A. Ni, and R. Gray. "Prophylaxis of deep-vein thrombosis in fractures below the knee." *Bone & Joint Journal* 91, no. 3 (2009): 388-394.
- [16] Leizorovicz, Alain, and Patrick Mismetti. "Preventing venous thromboembolism in medical patients." *Circulation* 110, no. 24 suppl 1 (2004): IV-13.
- [17] Bendz, B., K. Sevre, T. O. Andersen, and P. M. Sandset. "Low molecular weight heparin prevents activation of coagulation in a hypobaric environment." *Blood coagulation & fibrinolysis* 12, no. 5 (2001): 371-374.
- [18] Green top guideline no 37a: Reducing the risk of venous thromboembolism during pregnancy and puerperium; April 2015.
- [19] Weitz, Jeffrey I. "Low-molecular-weight heparins." *New England Journal of Medicine* 337, no. 10 (1997): 688-699.
- [20] Wolowacz, Sorrel E., Neil S. Roskell, Jonathan M. Plumb, Joseph A. Caprini, and Bengt I. Eriksson. "Efficacy and safety of dabigatran etexilate for the prevention of venous thromboembolism following total hip or knee arthroplasty-A meta-analysis." *Thrombosis and haemostasis* 101, no. 1 (2009): 77-85.
- [21] Bapat, Priya, Reuven Kedar, Angelika Lubetsky, Jeremy N. Matlow, Katarina Aleksa, Howard Berger, and Gideon Koren. "Transfer of dabigatran and dabigatran etexilate mesylate across the dually perfused human placenta." *Obstetrics & Gynecology* 123, no. 6 (2014): 1256-1261.